



Reptile respiratory medicine

Juergen Schumacher, Dr med vet, Dipl ACZM

*Department of Small Animal Clinical Sciences, College of Veterinary Medicine,
The University of Tennessee, Knoxville, TN 37996, USA*

Respiratory disease is commonly diagnosed in captive reptiles, and is a major cause of morbidity and mortality. Although all species of reptiles are susceptible, most commonly, chelonians and snakes present with acute or chronic respiratory tract disease. Environmental requirements for most reptile species are very specific and often difficult to meet in captivity. Suboptimal environmental conditions such as too high or too low temperature and humidity, inadequate diet and chronic stress (eg, poor cage design and/or incompatible cage mates) will result in an immunocompromised animal. A variety of infectious agents, including viral, bacterial, fungal and parasitic agents have been detected and associated with respiratory disease in reptiles, but noninfectious causes such as foreign bodies and trauma are also common.

Knowledge and understanding of the unique reptilian respiratory anatomy and physiology is mandatory for the successful diagnosis and treatment of respiratory disease. Respiratory disease may be the primary disease or may have developed secondary to underlying disease processes also requiring treatment. Although the initial approach to the reptilian patient presented with respiratory disease follows the same principles known from domestic animals, advanced diagnostic investigations, interpretation of diagnostic tests, as well as treatment protocols need to be modified due to the unique respiratory morphology and function of reptiles. The pathophysiology of many reptilian diseases, including respiratory tract disease, differs considerably from mammals. In addition, reptiles may respond differently to therapeutic regimen when compared to mammals. Prior to treatment, it is essential to determine the causative agent(s) for respiratory disease and correct improper husbandry practices to ensure optimal response of the patient to treatment.

E-mail address: jschumacher@utk.edu (J. Schumacher).

Pulmonary anatomy and function differs not only between orders of reptiles but also between genus and family [1,2]. Several reviews have been published on respiratory tract disease in different orders of reptiles, and new information on diagnostic procedures and therapeutics is rapidly becoming available [3–8]. The following article emphasizes the unique anatomic and physiologic characteristics of the reptilian respiratory tract, as well as the etiology, clinical signs, diagnosis and treatment of reptile respiratory disease.

Respiratory anatomy

The anatomy of the reptilian respiratory system is unique, and differs considerably from mammalian and avian species. Reptiles lack a functional diaphragm, and therefore the force to move air during inspiration and expiration comes from movement of respiratory muscles such as the intercostal, pectoral, and abdominal musculature causing changes in intrapulmonary pressure. A structure separating the thoracic and the abdominal cavities has been described in crocodilians and several lizards and tortoise species; however, this fascia-like structure does not aid in the movement of gas between the lungs and the environment. Differences in the structure and function of the respiratory system are present between orders of reptiles as well as between species from the same order [1,2]. Anatomic differences of the reptilian respiratory system have been recognized for many years, but there is inconsistency in the terminology used for the description of various pulmonary structures [1]. As in mammals and avian species, the reptile respiratory tract is divided into an upper and a lower part.

In snakes, air passes through the external nares, the nasal sinuses, the internal nares, and enters the glottis from the buccal cavity [9]. The glottis is located rostrally within the oral cavity, allowing the movement of air while swallowing large prey items. The trachea consists of incomplete cartilaginous rings and bifurcates into short bronchi at the level of the heart. Some snake species have a tracheal lung consisting of vascularized respiratory tissue [9]. The lungs are elongated, sac-like structures with the left lung being vestigial in most species, except in boid snakes. Depending on the species and the environment the snake has adapted to, the right lung lined with respiratory epithelium, joins with a caudal avascular, saccular lung lined with nonrespiratory epithelium. The lungs of aquatic snakes are lined with more respiratory epithelium than terrestrial species for more efficient gas exchange during prolonged periods of apnea.

In carnivorous lizards, the glottis is located rostrally, while in herbivorous species it is located more caudally at the base of a fleshy tongue. Like snakes, lizards have incomplete tracheal rings and the trachea bifurcates approximately at the base of the heart. The lungs of most lizard species are sac-like, single-chambered structures, and may extend caudally into an avascular airsac, which in some species occupies a major portion of the coe-

lomic cavity. Iguanids have a short intrapulmonary bronchus and possess multichambered lungs consisting of a small anterior chamber and a large posterior chamber. Agamid lizards lack an intrapulmonary bronchus [1].

In chelonians, air enters through the nares and passes through the nasal cavities lined by olfactory epithelium and mucosal epithelium [7,10]. The glottis is located at the base of the fleshy tongue, and often is not visualized in an awake patient. The trachea consists of complete tracheal rings and bifurcates into a left and right unbranched intrapulmonary bronchus at the thoracic inlet. All chelonians have paired, multichambered lungs that are located underneath the carapace, are relatively rigid, and may extend caudally to the cranial pole of the kidneys. The well-developed bronchi branch into small air passageways that terminate into alveolar tissue.

In crocodilians, the glottis is located behind the epiglottal flap, which seals the oral cavity while the animal is submerged. The lungs of crocodilians are multichambered, and they have the most complex lung of any reptilian order. The bronchi branch into multiple internal lobes. A septum separates the thoracic from the abdominal cavity.

Respiratory physiology

Reptilian respiratory physiology is unique, and differs considerably between orders and species. As in mammals, the major organ for gas exchange (oxygen and carbon dioxide) is the lung, although some species such as aquatic snakes and turtles are capable of gas exchange across the pharyngeal and cloacal mucosa, and the skin. Cutaneous gas exchange is more important in eliminating CO₂ rather than uptake of O₂. Some species of sea snakes (*Pelamis platurus*) eliminate approximately 74% of its CO₂ via cutaneous gas exchange [2]. Many reptiles, especially aquatic species, are capable of converting to anaerobic metabolism during long periods of apnea.

In comparison to mammalian lungs, reptilian lungs have high compliance values and are relatively easy to inflate. With greater compliance, the work of breathing is lower; thus, reptiles increase their minute volume by increasing their respiratory rate. In comparison to mammals, reptiles have larger lung volumes independent of their structural type [1]. However, the surface area for gas exchange is only approximately 20% of a mammal of comparative body mass.

Control of ventilation in reptiles is different from mammalian and avian species. In contrast to mammalian respiratory physiology, in which high carbon dioxide concentrations stimulate respiration, reptilian respiration is controlled by hypoxia and hypercapnia, as well as environmental temperature. Many species differences exist, depending on environmental adaptations. Different receptors increase ventilation during periods of low O₂ and high CO₂. In tortoises, respiratory rate increases during hypercapnia but decreases during hypoxia [2]. In most reptile species, hypercapnia causes

increases in tidal volume while periods of hypoxia will increase respiratory rate. The stimulus to breath in reptiles comes from low oxygen concentrations. The higher demand for oxygen during increased temperature or following prolonged dives in aquatic species is met by increasing the tidal volume and not the respiratory rate. Exposure of a reptile to high concentrations of inspired oxygen will decrease ventilation including a decrease in respiratory rate and tidal volume. Reptiles have the unique ability to tolerate varying degrees of hypoxia, and are capable to convert to anaerobic metabolism. Intrapulmonary shunts, representing the portion of pulmonary blood bypassing gas exchange, have been observed in reptiles. Shunts are most developed in testudines and sea snakes, and will increase with reduced lung volumes. Large intrapulmonary shunts reduce the efficiency of gas exchange in the lungs and consequently result in a reduction in arterial PO₂ concentrations [2].

Clinical signs

Owners often fail to recognize early or mild signs of respiratory tract disease in reptiles because they may be subtle and slow to develop. Consequently, many reptiles are presented in advanced stages of respiratory disease and a variety of clinical signs, including those associated with other organ systems than the respiratory tract, may be present. Although respiratory disease may present as the primary symptom, in many cases, especially chronically ill and septic reptiles, multiple organ systems may be affected. Prior to treatment, it is essential to determine if the animal has an upper and/or lower respiratory tract infection.

In snakes, serous to purulent nasal discharge, wheezing, accumulation of respiratory secretions within the oral cavity, and stomatitis are common clinical signs. In severe cases, increased respiratory efforts and dyspnea are also present. Due to the lack of a functioning diaphragm, snakes lack the mechanisms to expel respiratory secretions and debris from the trachea, thus the presence of fluid within the trachea results in a narrowed tracheal lumen. Typically, in these cases the presenting clinical signs are open-mouth breathing and extension of the front half of the body to facilitate movement of air through the trachea.

In lizards, clinical signs include nasal and ocular discharge, accompanied by rhinitis, conjunctivitis, and stomatitis. Bacterial abscesses within the oral cavity may cause displacement of the glottis and severe dyspnea. In chronically infected lizards, periorbital abscesses are frequently observed. Frequent sneezing with serous to mucoid discharge may also be present. In severe cases of pneumonia, increased respiratory efforts are often present.

In chelonians, nasal and ocular discharge, rhinitis and conjunctivitis are common clinical signs of upper respiratory disease. In chronically infected tortoises, cutaneous erosion and depigmentation around the nares are commonly seen. Rhinitis in tortoises is often multifactorial and caused by

a variety of Gram-negative organisms [11]. Stomatitis, with the presence of necrotizing lesions and abscesses, may be present with both upper and lower respiratory tract disease. In severe and chronic cases, especially with obstructive processes (eg, abscesses and accumulation of cellular debris within the nasal passageways and thickening of upper respiratory tract epithelium) open-mouth breathing may be present. In aquatic species buoyancy problems may be observed, and severely affected turtles are unable to dive due to accumulation of uni- or bilateral gas pockets within the lungs.

Many reptiles are presented with chronic respiratory tract disease and by the time of presentation clinical signs include pale, cyanotic membranes and multiple signs of disease may be present including lethargy, anorexia, egg-binding, and dysecdysis. In these patients, additional diagnostic tests are required to fully elucidate the extent of respiratory disease, as well as other organ system function.

Septicemia is often undiagnosed in reptiles, resulting in improper and unsuccessful treatment of the patient. In reptiles, septicemia most commonly originates from the gastrointestinal, urinary, or respiratory tracts. A presumptive diagnosis of septicemia can be made by physical findings, but a venous blood sample, aseptically collected and submitted for culture and sensitivity testing, is needed for confirmation. In some cases it is indicated to treat the animal for a suspected septicemia while laboratory results are pending. Broad-spectrum antimicrobial agents effective against common reptilian pathogens should be selected. It may become necessary to adjust antimicrobial drug selection based on culture and sensitivity results.

Respiratory emergencies

Treatment of respiratory emergencies in reptiles follows the same principles known from small animal emergency medicine [12]. In emergency situations, supplemental administration of oxygen via face mask is of short-term benefit. Establishment of a patent airway by endotracheal intubation or placement of a tracheostomy tube has priority if obstructive processes are present. The presence of large amounts of fluid and secretions within the tracheal lumen requires removal by suction. Once the reptile is stabilized, obstructive processes such as abscesses or foreign bodies within the oral cavity or tracheal lumen should be removed.

Emergencies of the upper respiratory tract

Pathologic conditions within the nasal cavity such as chronic rhinitis and granuloma formation do not present as an emergency in most reptiles. Obstructive processes within the oropharynx cause the majority of emergencies originating from the upper respiratory tract. Abscesses within the oral cavity are commonly seen in all orders of reptiles, and they may impair respiration if the location or size of the abscess results in displacement or

occlusion of the glottis. Foreign bodies such as plastic or wood may directly compromise the flow of air or may result in infection with subsequent abscess formation. In these cases, establishment of a patent airway by either endotracheal intubation or tracheostomy followed by debridement of the abscess and removal of the foreign body is indicated.

Emergencies of lower respiratory tract

Obstructive lesions of the trachea and the major airways are most commonly caused by foreign bodies, granuloma formation and, in some cases, by neoplastic processes. In addition to a physical examination, a diagnosis can be made by radiography and endoscopy of the lower respiratory tract. Depending on the size of the reptile, foreign bodies and masses can be removed endoscopically or by surgical intervention.

Pulmonary granulomas and neoplasia, as well as coelomic effusions, commonly caused by ruptured follicles may cause severe respiratory compromise and distress. Rapid accumulation of intracoelomic fluid and displacement of the lungs dorsally will often result in signs of severe respiratory impairment. In addition to respiratory support such as endotracheal intubation and intermittent positive pressure ventilation, intracoelomic fluid should be aspirated and characterized. The underlying cause should be treated following emergency stabilization of the reptile. Radiography, endoscopy, and ultrasonography are the most useful diagnostic tools to identify intracoelomic fluid as well as pulmonary lesions.

Reptiles are often presented with chronic pneumonia and severe impairment of pulmonary function. Physical examination, evaluation of hematologic and plasma biochemical parameters, collection of appropriate diagnostic samples such as tracheal washes for cytology and culture, as well as radiography are essential to fully elucidate the severity of pulmonary compromise and dysfunction (Fig. 1). In emergency cases, systemic antimicrobial therapy should be accompanied by nebulization and frequent aspiration of respiratory secretions from the trachea.

Infectious agents causing changes in capillary permeability may cause pulmonary edema in reptiles but the etiology may also include cardiac disease, hypoproteinemia (eg, renal disease, liver disease, and malnutrition) and exposure to toxic fumes.

Diagnostic tests and sample collection

Clinical evaluation of a reptile presented with primary signs of respiratory disease includes a detailed history and critical review of husbandry practices. This should be followed by a visual examination, physical examination, and appropriate diagnostic tests such as cytology, culture, radiography, and endoscopy. A systematic approach is recommended in all reptiles presented with respiratory tract disease. In many cases improper environmental conditions such as too low or too high temperature and hu-

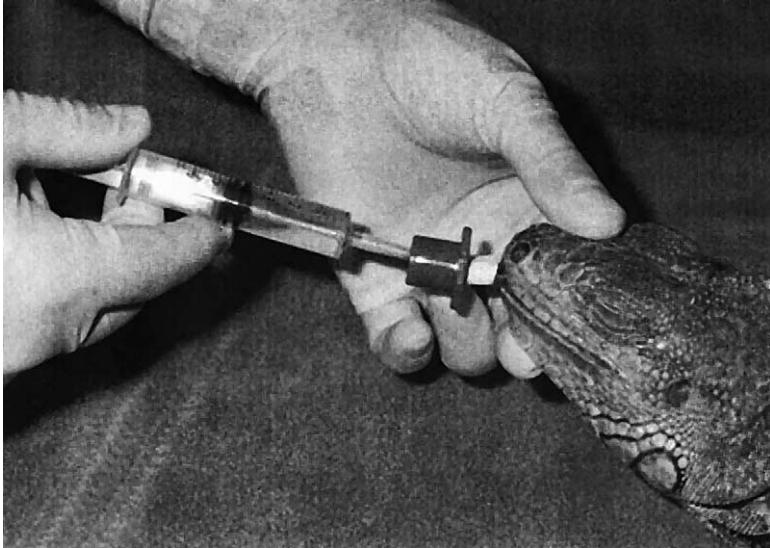

Fig. 1. Tracheal wash in an anesthetized green iguana (*Iguana iguana*) with pneumonia.

midity, inadequate diet, and chronic stress will predispose the reptile to the development of infectious diseases, including respiratory disease. A detailed history, including information on husbandry practices, hygiene procedures, and onset and progression of clinical signs should be obtained. In large reptile collections, the quarantine program, if present, should be evaluated.

A visual examination of the animal should evaluate overall body condition, mental status, and particular attention should be paid to the respiratory status. Mild signs of respiratory disease may include nasal and oral discharge as well as ocular discharge and conjunctivitis. Evidence of respiratory distress such as increased resting respiratory rate, labored breathing, open-mouth breathing, and visible signs of respiratory compromise should be noted (Fig. 2).

A physical examination with attention to the respiratory tract should also include evaluation of other major organ systems. Nasal and ocular discharges, if present, should be evaluated and submitted for diagnostic testing such as cytology and culture. The nares and the oral cavity should be examined for signs of infection and obstructive processes. Auscultation of the lungs is difficult at best in reptiles, and often will not give the desired information. Radiography is a very useful diagnostic tool for the detection of respiratory tract disease, especially in tortoises and lizards [13]. Radiography is of only limited value to assess the respiratory tract in snakes, unless severe pulmonary changes such as bacterial granulomas or neoplasia are present. In snakes, areas of increased pulmonary density such as bacterial granulomas are best visualized using a lateral projection. In lizards and snakes, standard views should be obtained including a lateral and dorsoventral

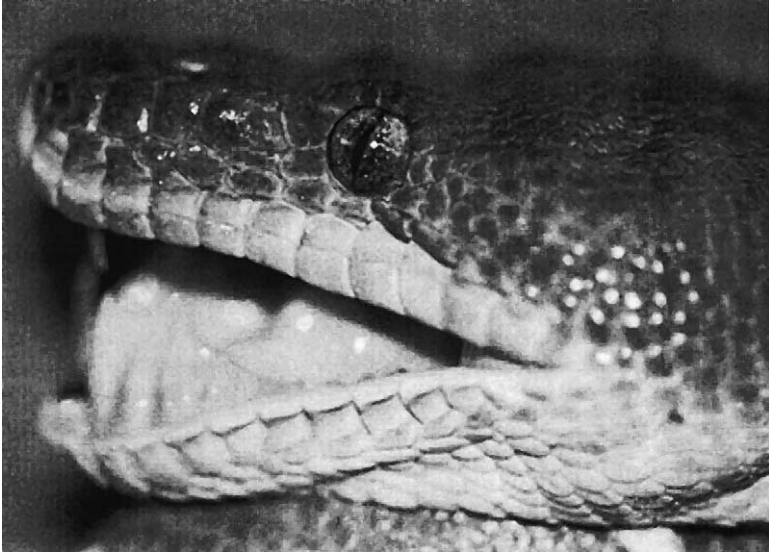


Fig. 2. Emerald tree boa (*Corallus caninus*) in severe respiratory distress characterized by open-mouth breathing.

view. In chelonians, three views are necessary to evaluate the respiratory tract, including a lateral, dorsoventral, and craniocaudal view. The latter allows for visualization of both lung fields and interstitial and alveolar opacities can best be demonstrated with this projection. It is essential to be familiar with the normal anatomy, including location of the lungs and extent of the air sacs, to appreciate any abnormalities.

Ultrasonography is a useful adjunct to other imaging techniques such as radiography, to aid in the diagnosis of discrete pulmonary masses. Ultrasonography offers the ability to noninvasively evaluate the morphology and extent of focal pulmonary changes such as granulomas and neoplasia. Diagnostic specimen such as aspirates, for cytology and culture, can be collected with ultrasound guidance.

Computed tomography (CT) has been applied successfully to obtain images of reptilian respiratory organs [14]. CT provides thin, cross-sectional images, and the technique is noninvasive. Although scans are usually done in transverse directions, computer programs are available to provide three-dimensional models of the images. In reptiles, CT scans can be obtained from the upper respiratory tract to diagnose acute or chronic conditions within the nasal cavities and sinuses. CT can also be applied to diagnose pathologic conditions of the lung such as pneumonia and masses. However, more information is needed to clearly describe normal anatomy of various organs including the respiratory tract in reptiles and their appearance in CT. Computed tomography can also be used to evaluate the progress of a disease and to stage treatment protocols.

Magnetic resonance imaging can be utilized in reptiles to identify pathologic changes of the respiratory tract [15]. Magnetic resonance imaging offers the advantage over other imaging techniques such as radiography in that soft tissue contrast is improved. To identify abnormal conditions, normal anatomy also needs to be described with this technique. The trachea and lung fields, including pulmonary septae, can readily be identified. Pulmonary changes such as edema, inflammatory conditions, and interstitial changes can also be detected with this imaging modality.

Endoscopy is commonly used in reptile medicine and will facilitate examination of the upper and lower respiratory tract of even small reptile species [16,17]. The nares, trachea, bronchi, lungs, and air sacs can be visualized with small, rigid, and flexible endoscopes. Diagnostic samples, such as biopsies and washes, can be collected and should be submitted for cytology, histology, and culture. Endoscopy is also a useful tool for detection and evaluation of focal changes such as granulomas. In chelonians, techniques to evaluate the lower respiratory tract, using a carapacial and prefemoral approach have been described [16].

A venous blood sample should be collected and hematologic and plasma biochemical analysis be made to identify abnormalities and systemic organ disease. Few serological tests are available for the diagnosis of infectious disease processes in reptiles. Exposure of snakes to ophidian paramyxovirus can be determined with a hemagglutination inhibition assay [18]. An enzyme-linked immunosorbent assay has been developed to detect antibodies to *Mycoplasma agassizii* in tortoises [19]. A polymerase chain reaction test is available for the detection of mycoplasma DNA in secretions of suspected tortoises [20]. An enzyme-linked immunosorbent assay to detect circulating antibodies to herpes virus has been developed as well as a polymerase chain reaction to demonstrate herpes virus DNA in tissues of infected tortoises [21,22].

In cases of rhinitis and upper respiratory tract disease, diagnostic samples can either be collected with a sterile swab or by nasal flush. The collected sample is then transferred into an appropriate culture medium for growth and identification of organisms. If lower respiratory tract disease is suspected such as tracheitis, bronchitis, or pneumonia, a tracheal or lung wash should be performed. In chelonians the presence of a fleshy tongue often obscures visualization of the glottis and passage of a sterile catheter. It is important to follow aseptic techniques since contamination of the sample with organisms from the oral cavity will render the sample inaccurate. The animal should be intubated with a sterile endotracheal tube, and depending on the size of the reptile, an appropriate-sized sterile catheter is inserted through the endotracheal tube into the trachea and sterile, physiologic saline (3–5 mL/kg) is administered followed by repeated gentle aspiration (Fig. 1). The collected material should be submitted for cytologic evaluation, parasite screening, bacterial and/or fungal culture, and sensitivity testing. If indicated, samples can also be submitted for viral isolation and electron

microscopy. Negative staining electron microscopy is an excellent and useful diagnostic tool for the detection of viral particles in fluids and secretions. Impression smears can be made from lesions or masses and evaluated cytologically.

Etiology

Both infectious and noninfectious agents have been associated with respiratory disease in reptiles [8]. Bacterial organisms, especially Gram-negative bacteria commonly isolated from reptiles with acute or chronic respiratory disease, are often opportunistic bacteria, present also in healthy animals. Under certain conditions, however, such as in an immunocompromised reptile, these organisms will often overgrow and can become primary pathogens.

Noninfectious agents

A variety of noninfectious conditions associated with respiratory disease are commonly seen in reptiles. Penetrating injuries to the lungs are often seen in lizards and snakes due to bite wounds from other pets. Crushing injuries to the carapace and subsequent injury to the underlying lung parenchyma is commonly found in chelonians hit by cars or lawn mowers.

In ball pythons (*Python regius*), cartilaginous granulomas have been reported originating from the tracheal cartilage rings [23]. Clinically, signs of respiratory distress such as open-mouth breathing as well as anorexia have been seen. The presence of lesions can be confirmed by radiography or endoscopic examination of the tracheal lumen.

Although infrequently reported in reptiles, the presence of neoplastic masses, within the major airways and the lung will result in respiratory compromise. Lymphoma has been reported in snakes, lizards, and chelonians, and is commonly associated with oral tissues and the lung [24]. Radiography and endoscopy are the most useful tools in the detection of space-occupying masses.

Foreign bodies are most commonly seen in lizards, especially in green iguanas (*Iguana iguana*) allowed free access of the house or apartment, as well as in chelonians. Plastic objects may accidentally become lodged within the oropharynx. Free-ranging aquatic turtles often present with a fishhook embedded within the oral cavity or the oropharynx. Trauma and inflammation of the surrounding tissue may result in a partial obstruction of the tracheal opening and respiratory distress.

Infectious agents

Infectious agents including viruses, bacteria, fungi, and parasites have been detected and associated with respiratory disease in reptiles [3,4,7].

In many cases, secondary bacterial infections complicate the diagnosis of a primary viral pneumonia. In patients with only temporary improvement of clinical signs following appropriate antimicrobial therapy, a viral etiology should be suspected and further testing is warranted.

Viral

Viral agents have been associated with outbreaks of respiratory disease and major morbidity and mortality in captive collections of reptiles. In some cases, however, they may go undetected due to the lack of more specific diagnostic procedures, such as viral isolation or electron microscopy.

In chelonians, herpesvirus infections are associated with stomatitis, rhinitis, tracheitis, and pneumonia [2]. A variety of chelonian species have been diagnosed with herpes virus infections, including aquatic and marine turtles. Lung, eye, and trachea disease has been described in farmed, juvenile green sea turtles (*Chelonia mydas*) [25]. Tortoises commonly infected with herpes virus are Mediterranean (*Testudo graeca*) and Hermann's (*Testudo hermanni*) tortoises [26,27]. Clinical signs of infected animals include serous to purulent nasal and ocular discharge. Anorexia and the presence of caseous necrotizing lesions within the oral cavity and trachea of affected tortoises are common findings. A diagnosis can be made by demonstration of intranuclear inclusions in cytologic or biopsy specimen, collected from oral lesions.

The best-described viral disease in reptiles is ophidian paramyxovirus infection of snakes. This disease primarily affects viperid snakes but also nonviperid snakes have been diagnosed with ophidian paramyxovirus. Several investigations in Europe and the United States have described the epidemiology, clinical, and pathologic findings as well as its viral characteristics [18]. Transmission of the virus is via respiratory secretions. Clinical signs of infected snakes are variable and include signs of respiratory tract disease such as stomatitis, open-mouth breathing, and nasal discharge. Purulent tracheal discharge may also be present. In advanced stages of the disease, signs of central nervous system disease may be seen. Histologically, an interstitial pneumonia and proliferation of the lining epithelial cells are the most significant findings. A serological test has been developed to determine exposure of snakes to the agent [18]. No specific treatment is available, and no vaccine has been developed to protect reptile collections from ophidian paramyxovirus. Treatment should include supportive care such as antimicrobial therapy, fluid therapy, and nutritional support. The most important factor is isolation of infected and exposed snakes to prevent transmission of the agent through a collection. Preventative measures include a strict quarantine program of at least 90 days to prevent introduction of the organism into a collection.

In imported caiman lizards (*Draecena guianensis*), epidemics of proliferative pneumonia have been associated with members of the Paramyxoviridae [28]. Clinical signs of infected animals included anorexia, dehydration, and possible respiratory distress.

Inclusion body disease of boid snakes primarily causes clinical signs of regurgitation, chronic wasting, and central nervous system disease but has also been associated with respiratory tract disease. Secondary bacterial infections caused by Gram-negative organisms typically cause upper and lower respiratory tract disease. Histologically, interstitial pneumonia with the presence of typical eosinophilic intracytoplasmic inclusion bodies in epithelial cells is seen [29]. There is no specific treatment for this infection, and isolation of infected and exposed snakes is recommended. Prevention is the most important factor, and all new arrivals should be quarantined for at least 90 days.

Bacterial

Bacterial pneumonia is often diagnosed in captive reptiles. Most bacterial organisms isolated from reptiles with respiratory disease are Gram-negative and part of the normal flora and the environment. Few bacterial organisms have been associated with primary respiratory infections. Organisms commonly isolated from reptiles with respiratory disease include *Pseudomonas* spp., *Klebsiella* spp., *Proteus* spp., *Aeromonas* spp., *Salmonella* spp., and *Staphylococcus* spp. Although part of the normal flora in healthy reptiles, isolation of these organisms from a tracheal wash of a reptile with respiratory disease is an indication of bacterial pneumonia. *Pasteurella testudines* has been isolated from Desert tortoises (*Gopherus agassizii*) with pneumonia [30]. Anaerobic infections have rarely been associated with respiratory disease although *Fusobacterium* spp, *Clostridium* spp, and *Bacteroides* spp have been isolated from reptiles [31].

Mycoplasmosis has been detected in captive and free-ranging populations of tortoises [10]. High morbidity and mortality is caused by *Mycoplasma agassizii* in California desert tortoises (*Gopherus agassizii*) and Florida Gopher tortoises (*Gopherus polyphemus*) [7]. Clinical signs include conjunctivitis and serous to purulent nasal discharge (Fig. 3). In chronic cases, degenerative changes of the nares may be present. Severely affected tortoises are often open-mouth breathing, anorectic and will have large quantities of purulent exudate within the nasal and oral cavity. In captive tortoises clinical signs appear to be more prominent in periods of stress due to seasonal environmental changes or improper husbandry. Supportive treatment includes nutritional support and fluid therapy. Systemic antimicrobial treatment with enrofloxacin accompanied by local administration of a 1:10 enrofloxacin solution to the nasal cavity is recommended. However, mycoplasmosis is a chronic infection and elimination of the organism may not be possible. Treatment of infected tortoises will reduce the severity of clinical symptoms, but infected animals should be considered carriers of the disease.

Fungal

Few reports have identified fungal organisms as a primary cause of respiratory disease in reptiles. Fungal elements are commonly isolated from



Fig. 3. California desert tortoise (*Gopherus agassizii*) with chronic upper respiratory tract disease (URTD) caused by *Mycoplasma agassizii*.

sick reptiles, but in most cases they appear to be secondary invaders following bacterial infections. Improper husbandry practices such as too high or too low environmental temperature, high humidity levels within the enclosure and chronic stress will promote growth of fungal organisms. Chelonians appear to be more susceptible to fungal infections than other orders of reptiles and *Candida* spp., *Aspergillus* spp., and *Penicillium* spp. have been isolated from chelonians with respiratory disease [5]. Collection of diagnostic specimen for the diagnosis of fungal pneumonia include tracheal washes, submitted for cytology and culture, as well as endoscopy and visualization of the respiratory tract including collection of biopsies and specimen for culture.

Parasitic

Primary parasitic infections of the respiratory tract are often accompanied by bacterial and fungal infections in reptiles. Pentastomids have been described in wild and captive reptiles, especially in snakes [32]. Clinically, increased respiratory efforts, including open-mouth breathing and severe respiratory compromise due to obstruction of major air passageways can be seen. Tracheal washes and demonstration of ova or bronchoscopy are needed to confirm a diagnosis. There is no effective chemical treatment and surgical removal of the worms is required. The by ingestion of ova, zoonotic potential of this infection should be considered prior to treatment.

Ascarids, especially in severe infections with high parasite loads, may also cause respiratory tract disease. Demonstration of typical eggs within fecal

material is diagnostic. *Kalicephalus* spp will migrate through lung tissue and will result in irritation of pulmonary tissue and subsequent secondary bacterial infections. *Rhabdias* spp, especially *Rhabdias fuscovenosa*, are found in the lung of infected snakes, and their direct life cycle will result in high parasite loads if left untreated. Secondary bacterial infections as well as severe inflammatory responses will result in pneumonia. Hookworm and lungworm infections are diagnosed by detection of larvae in a fecal or tracheal wash specimen.

Therapy

Prior to therapy, the environmental needs of the particular species should be met to ensure proper drug metabolism and immune system function. In debilitated and chronically sick reptiles, supportive measures such as fluid therapy and nutritional support should accompany systemic antimicrobial treatment. No treatment has been shown to be effective for viral diseases in reptiles although in cases of herpes virus infections, 5% acyclovir may improve lesions within the oral cavity in tortoises. The most effective way is prevention of the spread of viral diseases by isolation of infected and suspected tortoises from the collection.

Pharmacokinetic data for most antimicrobials used for the treatment of bacterial infections in reptiles are lacking, and effective therapeutic levels are unknown. In many cases, broad-spectrum antimicrobials effective against known reptilian bacterial pathogens are administered. Bacterial culture and sensitivity testing is recommended to ensure appropriate antimicrobial therapy. Broad-spectrum antimicrobials recommended for the treatment of reptile respiratory disease include amikacin, enrofloxacin, ceftazidime, and piperacillin because the majority of respiratory infections are caused by Gram-negative organisms. Anaerobic infections are most often treated with metronidazole (Table 1). In some cases multiple antimicrobials (eg, amikacin and ceftazidime) may be administered to effectively treat several Gram-negative isolates.

Antifungal agents have been used in reptiles with variable success due to the lack of pharmacokinetic data. In many cases, mixed fungal and bacterial infections are present, and antimicrobial treatment should accompany antifungal therapy. Antifungal agents most commonly used in reptiles include itraconazole, ketoconazole, and amphotericin B (Table 1). The latter can also be administered by aerosol therapy. Fungal infections often cause a granulomatous response in reptiles, thus making it difficult for the agent to reach the fungal organisms. Several agents often need to be combined, and if possible, isolated granulomas should be removed surgically. In chelonians with severe granulomatous pneumonia, a technique for placement of an intrapneumonic catheter for direct administration of antimicrobials and antifungal agents has been described [33].

Table 1

Antimicrobial, antifungal, and antiparasitic agents commonly used for the treatment of respiratory tract infections in reptiles

Drug	Dosage (mg/kg)	Route of administration	Frequency (h)
Amphotericin B	1	it	24
	1 mg/mL saline	Aerosol	12
Ampicillin	50	sc, im	12
Amikacin	5 then 2.5	im	72
	5 mg/mL saline	Aerosol	4–6
Ceftazidime	20	im	24–72
Cephalexin	20–40	po	12–24
Doxycycline	25–50	im	72
Enrofloxacin	5–10	im, po	12–48
Fenbendazole	50–100	po	Repeat in 14 days
Itraconazole	10–20	po	24
Ivermectin	0.2–0.4	im, sc	Repeat in 14 days
Ketoconazole	15–30	po	24
Metronidazole	20	po	48
Praziquantel	8	im, po	Repeat in 14 days
Piperacillin	100–200	im	24
	10 mg/mL saline	Aerosol	4–6
Trimethoprim-Sulfadiazine	30	im, so, po	24–48

Parasitic infections should be treated with appropriate antiparasitic agents. Ivermectin, fenbendazole, and metronidazole are most commonly used (Table 1). Concurrent antimicrobial therapy is often indicated for the treatment of secondary bacterial infections. In many cases, parasite infections are caused by husbandry and preventive care measures; therefore, these should be evaluated and corrected if indicated.

Upper respiratory tract disease is most effectively treated with systemic administration of antimicrobial agents accompanied by local treatment of affected areas of the upper respiratory tract. Rhinitis should be treated with local administration of a diluted antimicrobial agent (eg, 1:10 solution of enrofloxacin and saline) via nasal flush. A small gauge catheter tip or French catheter tubing can be inserted into the nares and the solution is administered twice daily for 10 days.

Corrective and supportive care measures accompanying antimicrobial or antifungal treatment include provision of proper environmental conditions, supplemental oxygen in cases of respiratory distress, fluid therapy in animals with an indication of volume depletion, as well as nutritional support. Mucolytic agents will often aid in the elimination of exudates.

Chelonians are frequently presented with traumatic, penetrating injuries to the carapace inflicted by cars or by predators. The underlying lung tissue may be exposed, and repair of the shell should be accompanied by supportive care measures such as appropriate analgesic therapy and long-term anti-

microbial therapy to prevent secondary bacterial infections. The prognosis in some cases is guarded, depending on the severity of the injury.

For the successful treatment of the reptile presented with respiratory tract disease it is essential to frequently monitor success of therapy such as improved breathing and decreased nasal discharge. Radiography will also aid in monitoring improvement of pulmonary lesions.

Aerosol therapy

Aerosol therapy is indicated in reptiles with severe, chronic respiratory disease to facilitate delivery of antimicrobials and/or saline and water directly to respiratory surfaces. Administration of antimicrobial agents by aerosol in conjunction with systemic antibiotic therapy will improve delivery of the agent to the source of infection. The antimicrobial agent delivered by aerosol therapy should be determined via culture and sensitivity testing. Saline and water will aid in loosening of viscous respiratory secretions and more efficient elimination of necrotic debris. Suctioning of the trachea following aerosol therapy will aid in the removal of these secretions because reptiles are unable to cough. Aerosols are most effectively delivered by nebulizers, which should be installed in an incubator to provide appropriate temperature and humidity for the reptile.

In addition to antimicrobials and saline, mucolytic and proteolytic agents can be administered; however, data on the effectiveness of these drugs in reptiles is lacking. Administration of bronchodilators should be exercised with caution due to potential side effects on the cardiovascular system. In general, selective beta 2-agonists such as salbutamol and terbutaline are preferred over nonselective sympathomimetic agents such as epinephrine and ephedrine.

For most reptiles aerosol therapy should be instituted three to four times daily for approximately 20 to 30 minutes. Prolonged aerosol therapy should be avoided because it has been shown to affect pulmonary function, including bronchospasm and pulmonary shunting [34].

Respiratory support and monitoring

Reptiles, presented with advanced or chronic respiratory disease require intensive supportive care and support of respiratory function. Similar principles known from small animal respiratory medicine apply to reptile patients [35]. Oxygen therapy is indicated in patients with impaired pulmonary function such as pneumonia, pulmonary edema, and suspected hypoxia. Arterial blood gas analysis is the most accurate means of determining the need for oxygen therapy; however, this is impractical in many reptile species because it requires a cut-down procedure. Also, due to the presence of cardiac shunts in reptiles, arterial blood gas analysis may not reflect lung gas composition. Cardiac shunting may regulate arterial blood gas composition independent from pulmonary ventilation [2]. Clinical signs such as dyspnea and tachycardia often indicates the need for supplemental oxygen.

The clinical response of the reptile to higher inspired oxygen concentrations will also aid in the diagnosis of hypoxemia. Techniques for effective administration of oxygen vary depending on the severity of clinical signs as well as the size of the reptile. The least stressful way to provide additional oxygen within a temperature-controlled environment is placement of the animal in an oxygen cage, especially if prolonged therapy is expected. More efficient means of oxygen administration are use of a face mask or nasal catheter and O₂ insufflation. A face mask is indicated for short-term administration of oxygen or in emergency situations. In larger reptile species, a nasal catheter can be used for prolonged administration of oxygen. The flow rate of oxygen for smaller reptiles (<10 kg body weight) should be 1–2 liters/minute while larger species (>10 kg body weight) will require flow rates up to 5 liters/minute. To prevent drying and irritation of the nasal mucosa, inspired oxygen should be humidified using a bubble humidifier, and the humidity within the cage should be increased.

In severe cases, especially in reptiles not responsive to external stimuli, administration of oxygen via endotracheal tube and positive pressure ventilation is necessary. Monitoring of clinical signs in response to therapy is recommended. Clinical signs of dyspnea, tachycardia or cyanosis should disappear if oxygen therapy is administered effectively.

Prevention

Many respiratory infections in reptiles are directly related to suboptimal husbandry including hygiene practices. Provision of appropriate environmental conditions is one of the key factors in the prevention of respiratory disease. In large reptile collections, a quarantine protocol is essential to prevent introduction of sick or carrier animals into an established collection and exposure of the resident reptiles to potentially new pathogens. During quarantine, which should last minimally 90 days, every reptile should have a thorough physical examination, including collection of a venous blood sample for hematologic and plasma biochemical determinations and fecal screens. Apparently sick animals should never be introduced into an established collection. Sick and exposed reptiles should be isolated and undergo diagnostic testing and treatment.

References

- [1] Perry SF. Lungs: comparative anatomy, functional morphology, and evolution. In: Gans C, Gaunt AS, editors. *Biology of the reptilia*. Vol. 19: morphology & visceral organs. St. Louis: Society for the Study of Amphibians and Reptiles; 1998. p. 1–92.
- [2] Wang T, Smits AW, Burggren WW. Pulmonary function in reptiles. In: Gans C, Gaunt AS, editors. *Biology of the reptilia*. Vol. 19: morphology & visceral organs. St. Louis: Society for the Study of Amphibians and Reptiles; 1998. p. 297–374.
- [3] Coke RL. Respiratory biology and diseases of captive lizards (sauria). *Vet Clin North Am Exotic Anim Pract* 2000;3:531–6.

- [4] Driggers T. Respiratory diseases, diagnostics, and therapy in snakes. *Vet Clin North Am Exotic Anim Pract* 2000;3:519–30.
- [5] Jacobson ER. Diseases of the respiratory system in reptiles. *Vet Med* 1978;73:1169–75.
- [6] Murray MJ. Pneumonia and normal respiratory function. In: Mader DR, editor. *Reptile medicine and surgery*. Philadelphia: W.B. Saunders; 1996. p. 396–405.
- [7] Origi FC, Jacobson ER. Diseases of the respiratory tract of chelonians. *Vet Clin North Am Exotic Anim Pract* 2000;3:537–49.
- [8] Schumacher J. Respiratory diseases of reptiles. *Semin Avian Exotic Pet Med* 1997;6:209–15.
- [9] Wallach V. The lungs of snakes. In: Gans C, Gaunt AS, editors. *Biology of the reptilia*. Vol 19: morphology G visceral organs. St. Louis: Society for the Study of Amphibians and Reptiles; 1998. p. 93–295.
- [10] Jacobson ER, Gaskin JM, Brown MB, et al. Chronic upper respiratory tract disease of free-ranging desert tortoises, *Xerobates agassizii*. *J Wildl Dis* 1991;27:296.
- [11] Stoakes LC. Respiratory system. In: Lawton PC, Cooper JE, editors. *Manual of reptiles*. Ames, IA: British Small Animal Veterinary Association, Iowa State University Press; 1992. p. 88–100.
- [12] Gibbons G. Respiratory emergencies. In: Murtaugh RJ, Kaplan PM, editors. *Veterinary emergency and critical care medicine*. St. Louis: Mosby-Year Book; 1992. p. 399–419.
- [13] Schumacher J, Toal RL. Advanced radiography and ultrasonography in reptiles. *Semin Avian Exotic Pet Med* 2001;10:162–8.
- [14] Gumpenberger M, Henninger W. The use of computed tomography in avian and reptile medicine. *Semin Avian Exotic Pet Med* 2001;10(4):174–80.
- [15] Straub J, Jurina K. Magnetic resonance imaging in chelonians. *Semin Avian Exotic Pet Med* 2001;10(4):181–6.
- [16] Divers SJ, Lawton MPC. Two techniques for endoscopic evaluation of the chelonian lung. *Proceedings of the 7th Annual Conference of the Association of Reptilian and Amphibian Veterinarians*, Reno, NV, 2000. Chester Heights, PA: Association of Reptilian and Amphibian Veterinarians; 2000. p. 123–5.
- [17] Schildger B, Wicker R. Endoskopie bei Reptilien und Amphibien-Indikationen, Methoden, Befunde. *Praktische-Tierarzt* 1992;73:516–26.
- [18] Jacobson ER, Gaskin JM, Wells S, et al. Epizootic of ophidian paramyxovirus in a zoological collection: pathological, microbiological and serological findings. *J Zoo Wildl Med* 1992;23:318–27.
- [19] Schumacher IM, Brown MB, Jacobson ER, et al. Detection of antibodies to a pathogenic *Mycoplasma* in the desert tortoise (*Gopheris agassizii*). *J Clin Microbiol* 1993;31:1454.
- [20] Brown DR, Crenshaw BC, McLaughlin GS, et al. Taxonomic analysis of the tortoise mycoplasmas, *M. agassizii* and *M. testudines* by 16S rRNA gene sequence comparison. *Int J Syst Bacteriol* 1995;45:348.
- [21] Origi F, Jacobson ER, Romero CH, Klein PA. Diagnostic tools for herpesvirus detection in chelonians. *Proceedings of the 7th Annual Conference of the Association of Reptilian and Amphibian Veterinarians*, Reno, NV, 2000. Chester Heights, PA: Association of Reptilian and Amphibian Veterinarians; 2000. p. 127–9.
- [22] Origi F, Jacobson ER, Romero CH, Klein PA. Tortoise herpesvirus and stomatitis-rhinitis in tortoises. *Proceedings of the 8th Annual Conference of the Association of Reptilian and Amphibian Veterinarians*, Orlando, FL, 2001. Chester Heights, PA: Association of Reptilian and Amphibian Veterinarians; 2001. p. 101–2.
- [23] Greenacre CB, Ritchie BW, Latimer KS. Treatment of cartilaginous hyperplasia in ball pythons. *Comp Cont Ed Pract Vet* 1999;21:633–7.
- [24] Garner MM, Raymond JT. Lymphoma in reptiles with special emphasis on oral manifestation. *Proceedings of the 8th Annual Conference of the Association of Reptilian and Amphibian Veterinarians*, Orlando, FL, 2001. Chester Heights, PA: Association of Reptilian and Amphibian Veterinarians; 2001. p. 165–9.

- [25] Jacobson ER, Gaskin JM, Roelke M, et al. Conjunctivitis, tracheitis and pneumonia associated with herpes-virus infection in Green Sea Turtles. J Am Vet Med Assoc 1986; 189:1020–3.
- [26] Marschang RE, Gravendyck M, Kaleta EF. Herpes virus in tortoises: investigation into virus isolation and the treatment of viral stomatitis in *T. hermanni* and *T. graeca*. J Vet Med 1997;44:385.
- [27] Mueller M, Sachse W, Zangger N. Herpesvirus-epidemie bei der griechischen (*Testudo hermanni*) und der maurischen Landschildkroete (*Testudo graeca*) in der Schweiz. Schweiz Arch Tierheilkd 1990;132:199.
- [28] Jacobson ER, Origgi F, Pessier AP, et al. Paramyxovirus infection in caiman lizards (*Draecena guianensis*). J Vet Diagn Invest 2001;13:143–51.
- [29] Schumacher J, Jacobson ER, Homer BL, et al. Inclusion body disease in boid snakes. J Zoo Wildl Med 1994;25:511–24.
- [30] Snipes KP, Biberstein EL. *Pasteurella testudinis* sp. nov: a parasite of desert tortoises. Int J Syst Bacteriol 1982;32:201.
- [31] Stewart JS. Anaerobic bacterial infections in reptiles. J Zoo Wildl Med 1990;21:180–4.
- [32] Hendrix CM, Blagburn BL. Reptilian pentastomiasis: a possible emerging zoonosis. Comp Cont Educ 1988;10:46–51.
- [33] Hernandez-Divers SJ. Pulmonary candidiasis caused by *Candida albicans* in a Greek tortoise (*Testudo graeca*) and treatment with intrapulmonary amphotericin B. J Zoo Wildl Med 2002;32(3):352–9.
- [34] Malik SK, Jenkins DE. Alteration in airway dynamics following inhalation of ultrasonic mist. Chest 1972;62:660–4.
- [35] Court MH. Respiratory support of the critically ill small animal patient. In: Murtaugh RJ, Kaplan PM, editors. Veterinary emergency and critical care medicine. St. Louis: Mosby-Year Book; 1992. p. 575–92.